



PATIENT

Cali Metzger

SPECIES

Canine

BREED

Golden Retriever

SEX

Female Spayed

AGE

8.5 years

WEIGHT

84lbs

INTERPRETED BY

Maggie Machen Lamy,
 DVM DACVIM
 (Cardiology)

IMAGING PERFORMED BY

Crystal Hill, RVT

HOSPITAL NAME

Headon Forest Animal
 Hospital

REFERRING VET

Dr. Van Monsjou

INVOICE

46783

DATE

2/10/26

PRESENTING CLINICAL SIGNS

History: Recheck echo – diagnosed with diet-related cardiomyopathy 3/2025. Improved upon reassessment. Doing well on now traditional diet.

-Current medications: Vetmedin 12.5mg BID, Fortekor 20mg SID, Spironolactone 50mg SID. Lasix was discontinued.

-Pertinent previous echo findings (8/2025 MML): Borderline LVE (5.0/3.7cm): FS: 26%, LA normalized: 3.1.

ECHOCARDIOGRAM FINDINGS

2D, m-mode, color flow and doppler imaging is available. Mild diffuse thickening of mitral valve leaflets with no prolapse into the left atrial lumen. No mitral regurgitation with a normal left atrial dimension. Normal LV diameter with borderline systolic function. The tricuspid valve appears normal with no significant tricuspid regurgitation. Normal right atrial and ventricular diameter and morphology; no overt evidence of pulmonary arterial hypertension. The pulmonic and aortic valves are normal in morphology and mobility. Normal LVOT and RVOT velocities. Trace aortic and no pulmonic insufficiency. No pericardial or pleural effusion noted. No obvious cardiac masses.

CARDIAC CHART

CANINE CARDIAC PARAMETERS	MR VMAX (m/s)	TR VMAX (m/s)	LA/AO (Boon method)	LA/AO (Heart Base; Swe)	FS (%)	EF (%)	EPSS (cm)
NORMAL PARAMETER	4.5-5.5	<2.7	1.3	<1.6	28-40	40-100	<0.6
PATIENT	NA	NA	NM	1.3	27	50	0.5
CANINE CARDIAC PARAMETERS	HR (BPM)	AV VMAX (m/s)	PV MAX (m/s)	BODY WEIGHT (kg)	LA 2D short axis Base view (cm)	LVIDd Avg; 2D and m-mode short axis (cm)	LVIDs Avg; 2D and m-mode short axis (cm)
NORMAL PARAMETER	50-100	0.7-1.7	0.7-1.6	BELOW	BELOW	BELOW	BELOW
PATIENT	NM	1.8	1.1	38.1	3.0	4.4	3.2
*Normal chamber parameters expressed as a mean value (SD)				3	1.27 (5.3)	2.46 (2.46)	1.36 (5.5)
BODY WEIGHT DEPENDENT PARAMETERS				5	1.40 (4.5)	2.74 (5.2)	1.60 (4.7)
*Note: All measurements based upon multi-modal images and methods. An average value is reported.				10	1.50 (3.8)	3.27 (3.5)	2.06 (3.1)
				15	1.83 (2.0)	3.71 (2.4)	2.43 (2.1)
				20	2.02 (1.9)	4.14 (2.2)	2.80 (2.0)
				25	2.18 (2.4)	4.48 (2.9)	3.10 (2.5)
				30	2.33 (3.3)	4.83 (3.9)	3.39 (3.4)
				35	2.48 (4.3)	5.17 (5.0)	3.69 (4.5)
				40	2.62 (5.2)	5.48 (6.1)	3.96 (5.4)
				50	2.88 (7.1)	6.07 (8.3)	4.46 (7.4)

INTERPRETATION OF THE FINDINGS & FURTHER RECOMMENDATIONS

Persistent improvement comparing serial exams. The LV has normalized with borderline function which is great news. Despite the borderline nature of the findings, no significant valve leaks are identified and the LA is normal.



PATIENT

Cali Metzger

SPECIES

Canine

BREED

Golden Retriever

SEX

Female Spayed

AGE

8.5 years

WEIGHT

84lbs

INTERPRETED BY

Maggie Machen Lamy,
 DVM DACVIM
 (Cardiology)

IMAGING PERFORMED BY

Crystal Hill, RVT

HOSPITAL NAME

Headon Forest Animal
 Hospital

REFERRING VET

Dr. Van Monsjou

INVOICE

46783

DATE

2/10/26

Given these findings it is reasonable to continue to wean the medications as below. Periodic monitoring is advised lifelong; however, the prognosis is open at this time.

Omega fatty acid supplementation and mild salt restriction may be of some long-term benefit.

Anesthetic risk is considered mild if needed. Cardiac protective drug choices (opioid/benzodiazepine premedication, propofol or alfaxalone induction, isoflurane gas) are recommended. Pre-oxygenate for 5-10 minutes prior to induction. Monitor for arrhythmias, hypotension, and hypoxia both intra and post-operatively and intervene as necessary. Mild IV fluid restriction is recommended to avoid fluid overload. Avoid heart rate stimulating drugs such as atropine unless clinically indicated.

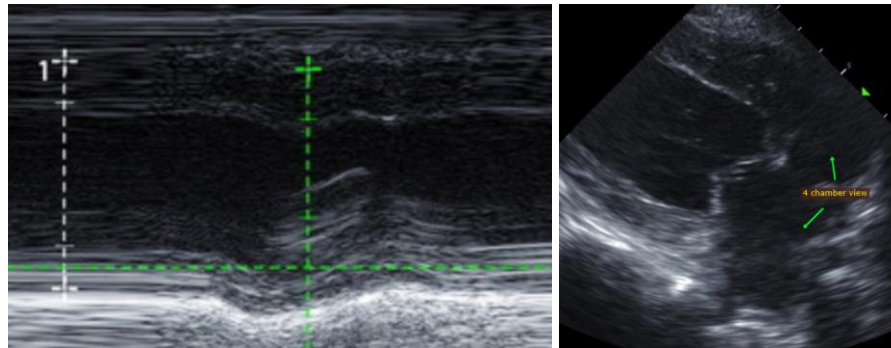
Monitor for development of a cough, labored breathing, exercise intolerance or collapse episodes.

PLAN

Discontinue the ACE-I and Spironolactone. If doing well in 2 weeks, discontinue Pimobendan.

Recommend conservative monitoring with a recheck echocardiogram in 6 months, sooner if any development of clinical signs or a heart murmur.

IMAGES



The information and recommendations provided are based on the images presented by the referring veterinarian. No evaluation can be communicated regarding pathology that was not visible in the image/video clips provided.

Thank you for this referral. This report was generated using transcription software, and minor dictation errors may be present. If the clinical or image interpretation does not parallel your findings or if I can be of any further assistance, please contact me.

Maggie Machen Lamy, DVM
Diplomate of the American College of Veterinary Internal Medicine (Cardiology)
 info@sonopath.com